

---

# NewFill for Skin Augmentation: A New Filler or Failure?

ROB C. BELJAARDS, MD, PHD,\* KEES-PETER DE ROOS, MD, PHD,† AND FRANK G. BRUINS, MD†

\*Department of Dermatology, Kennemer Gasthuis, Haarlem, the Netherlands; †Department of Dermatology, Bernhoven Ziekenhuis, Veghel, the Netherlands

---

**BACKGROUND.** New injectable materials for skin augmentation that promise to be the ideal filling material are introduced every year. Recently, we treated three patients with adverse reactions to a new substance for skin augmentation: polylactic acid (NewFill, Ashford Aesthetics Inc, Belgium).

**OBJECTIVE.** To present three cases in which serious adverse reactions had occurred after skin augmentation with a new filling substance, polylactic acid (NewFill). Because an identical substance (Sculptra, Aventis Pharmaceuticals, Bridgewater, NJ, USA) was recently introduced in the United States, we want to alert future users of these substances to possible adverse events.

**MATERIALS AND METHODS.** We report three cases with serious adverse events more than 12 months after skin augmentation with polylactic acid (NewFill). They were treated with intralesional steroid therapy and topical imiquimod application.

**RESULTS.** Both intralesional steroid therapy and topical imiquimod application lead to moderate results. If feasible, surgical excision is the best available option.

**CONCLUSIONS.** Great care should be taken when polylactic acid is used for intradermal injection because giant cell granulomatous reactions may be the result. Other than surgical excision, effective treatment options are lacking.

ROB C. BELJAARDS, MD, PHD, KEES-PETER DE ROOS, MD, PHD, AND FRANK G. BRUINS, MD, HAVE INDICATED NO SIGNIFICANT INTEREST WITH COMMERCIAL SUPPORTERS.

---

OVER THE last decade, there has been increasing interest in cosmetic treatment possibilities, especially for facial wrinkles. A higher quality of life at an increasingly older age for people living in the western hemisphere seems to influence this demand. In the United States alone, it has been estimated that 2.7 million people are treated with botulinum toxin A every year. Other options include skin augmentation with a diversity of substances, the so-called “fillers” or “injectables.”

Fillers can be divided into two groups: biodegradable materials that are used for direct—albeit temporary—augmentation, such as hyaluronic acid, or bovine collagen and nonbiodegradable materials, such as silicone oil or polymethylmethacrylate in combination with bovine collagen, which require some time to obtain a permanent result owing to encapsulation.

Scientists and physicians alike are still trying to find the ideal filler: a nonallergenic, nontoxic, nonmigratory replacement for the lost collagen or subcutaneous fat. The ideal filler should be easy to use with a direct result and no adverse effects. New materials that promise to be the ideal filler are introduced every year.

Recently, we saw three patients who had been treated with a relatively new substance for skin augmentation: polylactic acid (PLA) (NewFill, Ashford Aesthetics Inc,

Belgium). NewFill is the name of the substance outside the United States. It was introduced in the Netherlands in 2000. Sculptra is the name of the substance as marketed in the United States. The components of both NewFill and Sculptra are considered to be identical (<[http://www.fda.gov/ohrms/dockets/ac/04/slides/4031s1\\_01\\_SCULPTRA.ppt](http://www.fda.gov/ohrms/dockets/ac/04/slides/4031s1_01_SCULPTRA.ppt)>). Five studies were recently concluded. Two studies are from Europe and have been published,<sup>1,2</sup> and three studies are from the United States. All studies included only human immunodeficiency virus (HIV)-positive patients with significant and visible lipoatrophy of the face, and all were single-center studies. None of the studies were randomized, controlled, or blinded.

Publications of long-term results (longer than 2 years) with this new filler on large patient numbers do not exist. Because of the resorbable nature of this material, which has also been used as a subcutaneous suture, few side effects are expected by the manufacturer. However, we present three patients who developed granulomatous skin reactions 12 months or more after dermal injection with PLA (NewFill). In this article, we present their histories.

## Case 1

A 53-year-old woman presented with many disfiguring, symptomless facial strands, which had appeared a few months earlier. She had been treated 18 months before with NewFill injections (3 mL reconstituted in sterile water) for her facial wrinkles. In the period before or after

---

Address correspondence and reprint requests to: Kees-Peter de Roos, MD, PhD, Department of Dermatology, Ziekenhuis, Bernhoven, PO Box 10.000, Veghel, the Netherlands.

these injections, she had not undergone any other invasive cosmetic treatment.

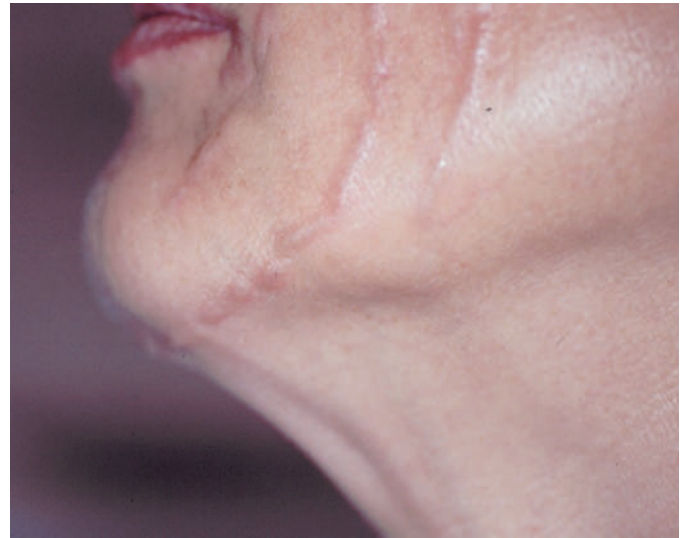
On examination, her face showed many 5 to 6 mm-wide palpable strands in the nasolabial fold, on the cheeks, along the vermillion border of the lips, and on the neck (Figures 1 and 2). According to the patient, the strands were in the exact regions in which she had been treated with NewFill.

Histology showed a flat epidermis with extensive intracutaneous foreign-body giant cell granulomas surrounding amorphous foreign-body material, double-breaking with polarized light. The upper parts of the dermis showed no abnormalities, apart from a few perivascular lymphocytes (Figure 3).

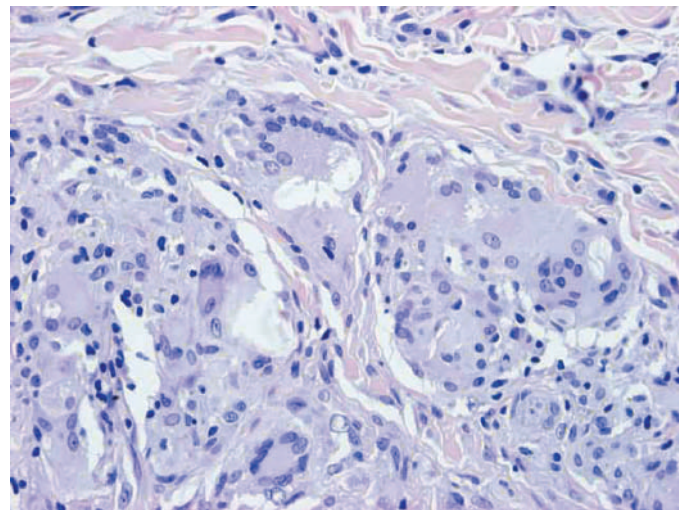
Treatment consisted of intralesional (Kenacort, Bristol Meyer Squibb b.v., Woerden, the Netherlands) corticosteroid injections and 5% imiquimod cream (Aldara, 3M, St Paul, MN, USA), without any visible result.

## Case 2

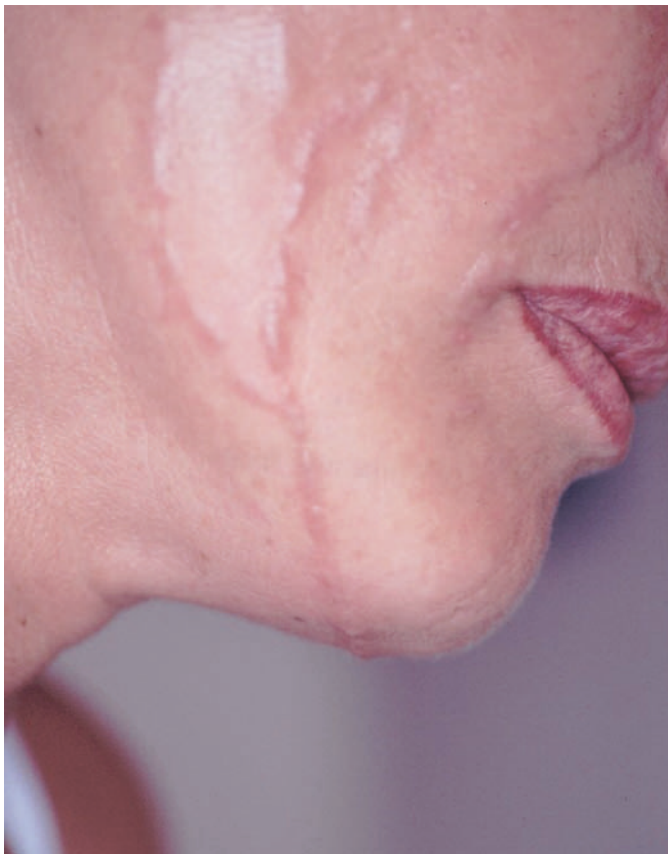A 46-year-old woman was referred for a second opinion because of facial nodules (Figure 4). Twenty-two months earlier, her facial wrinkles had been treated with NewFill injections. In two sessions, with a 10-week interval, 1 mL



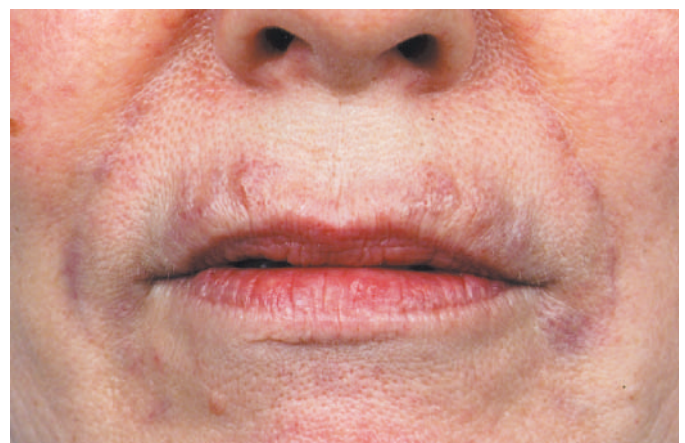**Figure 2.** Palpable and visible strings on the chin and cheek (case 1).



**Figure 3.** Histology with foreign-body giant cell reaction (case 1) (hematoxylin-eosin stain;  $\times 400$  original magnification).



**Figure 1.** Visible and palpable strings on the cheeks and upper lip (case 1).



**Figure 4.** Nodules in upper lip, nasolabial folds, and chin (case 2).

NewFill (3 mL reconstituted in sterile water) and 0.75 mL NewFill (2.25 mL reconstituted in sterile water), respectively, were injected. She had not been treated with any other substance for skin augmentation.

After 12 months, she slowly developed strands and nodules along the treated wrinkles. Elsewhere, she received intralesional injections with corticosteroids twice, without any effect.

On examination, many painless, livid, subcutaneous nodules and strands were observed in the glabellar region, the nasolabial folds, the vermillion border of the lips, and the chin fold.

Histology showed, in the deep reticular dermis, foci of inflammatory cells, consisting of lymphocytes, histiocytes, and many multinucleate giant cells. On using polarized light, these foci appeared to be arranged around double-breaking foreign-body material (Figures 5 and 6). There was no histologic sign of extra collagen production.

Treatment with topical imiquimod cream gave no result. At the moment, she is being treated with intrale-

sional steroid (Depomedrol, Pharmacia b.v., Woerden, the Netherlands) injections.

### Case 3

A 35-year-old woman presented with periocular nodules. Two years earlier, her crow's-feet lines were treated elsewhere with NewFill injections (1 mL reconstituted in sterile water).

After approximately 1 year, she gradually developed visible and palpable superficial nodules around her eyes. The above-mentioned treatment was the first invasive cosmetic treatment she had ever received.

On examination, the lateral periocular skin showed many livid to white intracutaneous nodules. Histology showed an extensive foreign-body giant cell reaction surrounding double-breaking material, as well as many lymphocytes in the immediate vicinity.

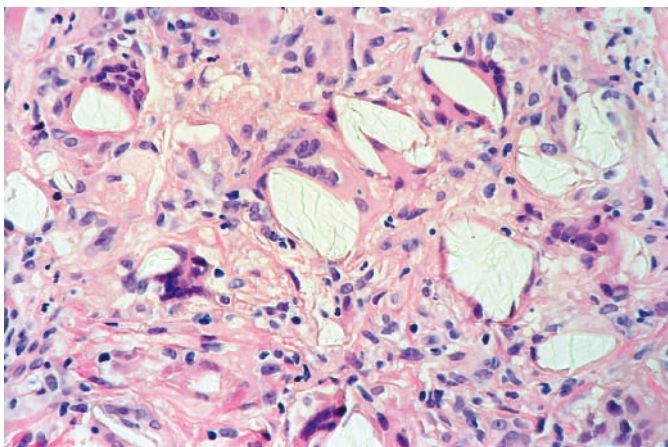
Because of the firmness of the nodules, intralesional corticosteroid injections could not be performed in the periocular region. The largest nodules were excised under local anesthesia, with a satisfactory result.

### Discussion

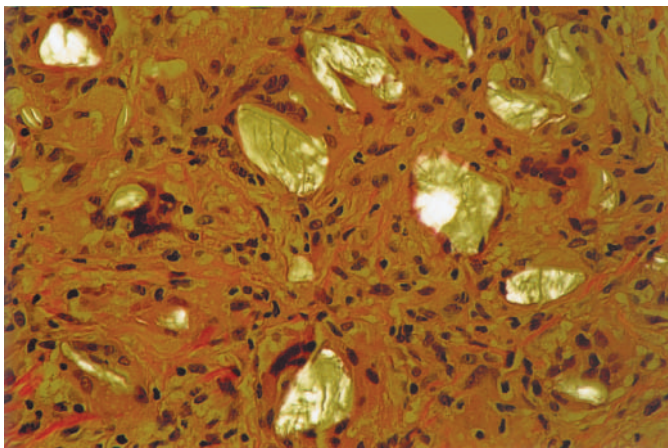
For the treatment of facial wrinkles, many injectables are available, biodegradable and nonbiodegradable. With the exception of autologous fat, in all other materials, foreign-body material is used. Consequently, the reactivity of the immune system in varying percentages has been described for all materials, resulting in a lymphocyte and often histiocytic reaction with granuloma formation.<sup>3-8</sup>

In the quest for a nontoxic and nonallergenic implant with a supposedly ideal combination of both resorbability and collagen formation, PLA has been used. It is a synthetic and resorbable molecule obtained after the polymerization of lactic acid monomers. Lactic acid has more than one spatial configuration (L-lactic acid and D-lactic acid). Usually, a mixture or copolymer is made of poly-L-lactic acid (L-PLA), poly-D-lactic acid (D-PLA), and/or glutamate acid. The amount of resorbability can be influenced by polymerization of different volumes of L-lactic acid, D-lactic acid, and glutamate acid. L-PLA has a long resorption time: the half-life of L-PLA has been estimated to be 31 days,<sup>9</sup> with a total resorption after 80 weeks.<sup>10</sup> Because of its biologically neutral nature and its resorbability through hydrolysis, L-PLA has been applied clinically for many years, especially in implants for facial reconstructive surgery and in suture material, such as Dexon II (Davis & Geck, Wayne, NJ, USA) and Vicryl (Ethicon Inc, Johnson & Johnson, Somerville, NJ, USA).

NewFill is also based on L-PLA. However, in the presented case histories, the substrate could still be demonstrated on histologic examination. The residual material subsequently led to a (delayed) foreign-body reaction. In



**Figure 5.** Histology with foreign-body giant cell reaction (hematoxylin-eosin stain;  $\times 400$  original magnification) (case 2).



**Figure 6.** Histology ( $\times 400$  original magnification with polarized light: foreign-body material) (case 2).

case 2, even 2 years after the injection, foreign-body material was still present, which is much longer than the aforementioned 80 weeks of total resorption time of L-PLA. It is important to realize that NewFill not only contains L-PLA. A freeze-dried vial also consists of 25% sodium carmellose and 35% pyrogen-free mannitol as a cryoprotective agent (product information from Ashford Aesthetics Inc).

One vial of NewFill contains 367 mg of solid material (150 mg L-PLA), which must be reconstituted with 3 mL of sterile water. In the cases we described, the advised amount of injected substance was a maximal 2 mL per session, divided in one or several sites. In case of correction of volume defects, it was advised to deposit the substance subcutaneously, but in case of rhytids, it was advised to inject it in the upper or mid-dermal layer.

The foreign-body reaction demonstrated in our three cases cannot be just the result of a too superficial injection technique or of an inadequate reconstitution of the material. One could speculate that the amount injected per session has been too high. However, it seems more likely that the reaction demonstrated in these three cases is due to the aberrant reactivity of the recipient to the material. It is striking that in none of the three cases was freshly produced collagen histologically demonstrable.

The treatment of granulomas as a result of injected foreign material is very difficult, especially in those cases in which the implant has not been resorbed.

Next to surgical removal of this implant, injections of corticosteroids with or without 5-fluorouracil belong to the therapeutic possibilities. Recently, a favorable effect of locally applied imiquimod on a foreign-body reaction after silicone injections was reported in the literature.<sup>11</sup> Considering this, in two of the cases, the granulomas were treated with 5% imiquimod cream, unfortunately without result. Imiquimod is an immune modulator, functioning as an up-regulator of the immune response. In these three cases, however, the histiocytic reaction is not so much related to antigens in connection with a lymphocyte reaction (immune response) as it is to surface proteins on the foreign-body material.

The risk of the use of polymers as fillers of rhytids was stressed in an earlier publication by Maas and colleagues in this journal.<sup>7</sup> NewFill was initially considered to be a favorable exception. Recently, several studies have become available in which the positive results and side effects of the use of NewFill in HIV-positive patients were presented.<sup>1,2,12</sup> Although these three studies mention the occurrence of granulomas at the site of the injection, the authors qualify these as "minor." These studies also report a follow-up period of less than 2 years. Moreover, these were all patients with a deficit immune response.

Although the foreign-body reaction is not due to the technique, certainly, the poor technique exacerbated the clinical manifestation. Because of the side effects we have

described, the current recommendations for reconstitution of Sculptra are 5 mL of sterile water and injections only at the subcutaneous dermal interface. No longer is the mid-, superficial, or even deep dermal layer recommended. The instructions also stress the importance of nonoverlapping injections in the areas of the face inferior to the zygoma and small deep 1 mL droplets in thicker areas such as the cheek and 0.05 mL in the temple area. In addition, to avoid the clumping of the material, extensive massage immediately after the injection and by the patients nightly is recommended.

The histories of our three patients, however, should make any physician using NewFill apprehensive about the possible long-term side effects as described. One can speculate that the material should be injected at a deeper level into the skin or even subcutaneously to avoid the giant cell reaction. As long as persons with an increased risk of side effects or complications cannot be recognized beforehand, and because there are currently no tests available, the use of foreign-body materials for tissue augmentation, such as polymers, may be a risky business.<sup>13</sup> Fillers that have been used for many years or those consisting of autologous material should be preferred before real long-term results are available.

## References

1. Moyle G, Lysakova L, Brown S, et al. A randomized open-label study of immediate versus delayed poly(lactic acid) injections for the cosmetic management of facial lipoatrophy in persons with HIV infection. *HIV Med* 2004;5:82-7.
2. Valantin MA, Aubron-Olivier C, Ghosn J, et al. Poly(lactic acid) implants (New-Fill®) to correct facial lipoatrophy in HIV-infected patients: results of the open-label study VEGA. *AIDS* 2003;17:2471-7.
3. Heise H, Zimmermann R, Heise P. Temporary granulomatous inflammation following collagen implantation. *J Craniomaxillofac Surg* 2001;29:238-41.
4. Bigata X, Ribera M, Bielsa I, Ferrandiz C. Adverse granulomatous reaction after cosmetic dermal silicone injection. *Dermatol Surg* 2001;27:198-200.
5. Rudolph CM, Soyer HP, Schuller-Petrovic S, Kerl H. Foreign body granulomas due to injectable aesthetic microimplants. *Am J Surg Pathol* 1999;23:113-7.
6. Honig JF, Brink U, Korabiowska M. Severe granulomatous allergic tissue reaction after hyaluronic acid injection in the treatment of facial lines and its surgical correction. *J Craniofac Surg* 2003;14:197-200.
7. Maas CS, Papel RD, Greene D, Stoker DA. Complications of injectable polymers in facial augmentation. *Dermatol Surg* 1997;23:871-7.
8. Lemperle G, Morhenn VV, Charrier U. Human histology and persistence of various injectable filler substances for soft tissue augmentation. *Aesthetic Plast Surg* 2003;27:354-66.
9. Spenlehauer G. Microsphères à base de cisplatine et de polymères biorésorbables du type poly-alpha-hydroxy-acides pour chimio-embolisation. Thèse de Sciences Pharmaceutiques 1987;6:387-94.
10. Athanasiou KA, Niederauer GG, Agrawal CM, Landsman A. Applications of biodegradable lactides and glycolides in podiatry. *Implantable Biomaterials* 1995;12:475-95.
11. Baumann LS, Halem ML. Lip silicone granulomatous foreign body reaction treated with aldera (imiquimod 5%). *Dermatol Surg* 2003;29:429-32.

12. Cheonis N. New-Fill to treat facial wasting. *BETA* 2002;15(2):10–5.  
 13. Lombardi T, Samson J, Plantier F, et al. Orofacial granulomas after

injection of cosmetic fillers. Histopathologic and clinical study of 11 cases. *J Oral Pathol Med* 2004;33:115–20.

## Commentary

Those of us with primarily “filling” practices have long been awaiting the US Food and Drug Administration’s approval of Sculptra (poly-L-lactic acid). As American dermatologists, we have been forced to make do with temporary crease fillers, such as the hyaluronic acids or collagens, or rely on the more global (albeit often unpredictable and arduous) filling with autologous fat. The excitement over the US launch of Sculptra was tempered by the experience of our European colleagues, who had all but abandoned its use owing to side effects such as described in this article. It is therefore critically important to follow the current

recommendations on dilution and administration, namely, reconstitution with a minimum of 5 mL of water and deep dermal or even subcutaneous injections. It is also important to recognize that unlike the mainstay fillers hyaluronic acid and collagen, poly-L-lactic acid is used to recontour the face similar to the way in which one would inject fat. In terms of the success of this filler, educating our peers and patients is the best way to avoid adverse effects and sequela.

LISA DONOFRIO, MD  
*New Haven, CT*

## Commentary

All polymers are not created equal. Hylaform and Restylane are polymers that are both safe and effective. With hyaluronic acids, it is not the structure as polymer but rather the protein load of the agent that creates the potential for an adverse hypersensitive reaction. In a recent article in *Aesthetic Surgery*, a series of 100 immunocompetent patients were treated with NewFill and Sculptra. There were 5 cases of infection, 12 cases of granuloma, and 3 cases of long-term allergic reaction.<sup>1</sup> This indicates that, although this agent provides a significant benefit to individuals with lipodystrophy secondary to highly active antiretroviral therapy or possibly the long-standing disease process itself, its use should be avoided in individuals with normal immune function-

ing. This conclusion is further supported by the data presented in this article. This should be added to the references cited in the article.

ARNOLD W. KLEIN, MD  
*Beverly Hills, CA*

ARNOLD W. KLEIN, MD, IS A CONSULTANT FOR MEDICIS.

## Reference

1. Saylan Z. Facial fillers and their complications. *Aesthet Surg J* 2003;23:221–4.